

Pelvic Floor Dysfunction in women and prolapse surgery

Mr Firas Younis

Colorectal surgeon

Luton & Dunstable University Hospital

Definition

- Inability to control faeces and to expel it at a proper place and at a proper time.
- Maintenance of continence depends on the following:
 - Stool consistency
 - Colorectal function and activity
 - Harmonious Fxn of The internal and external anal Sphincters

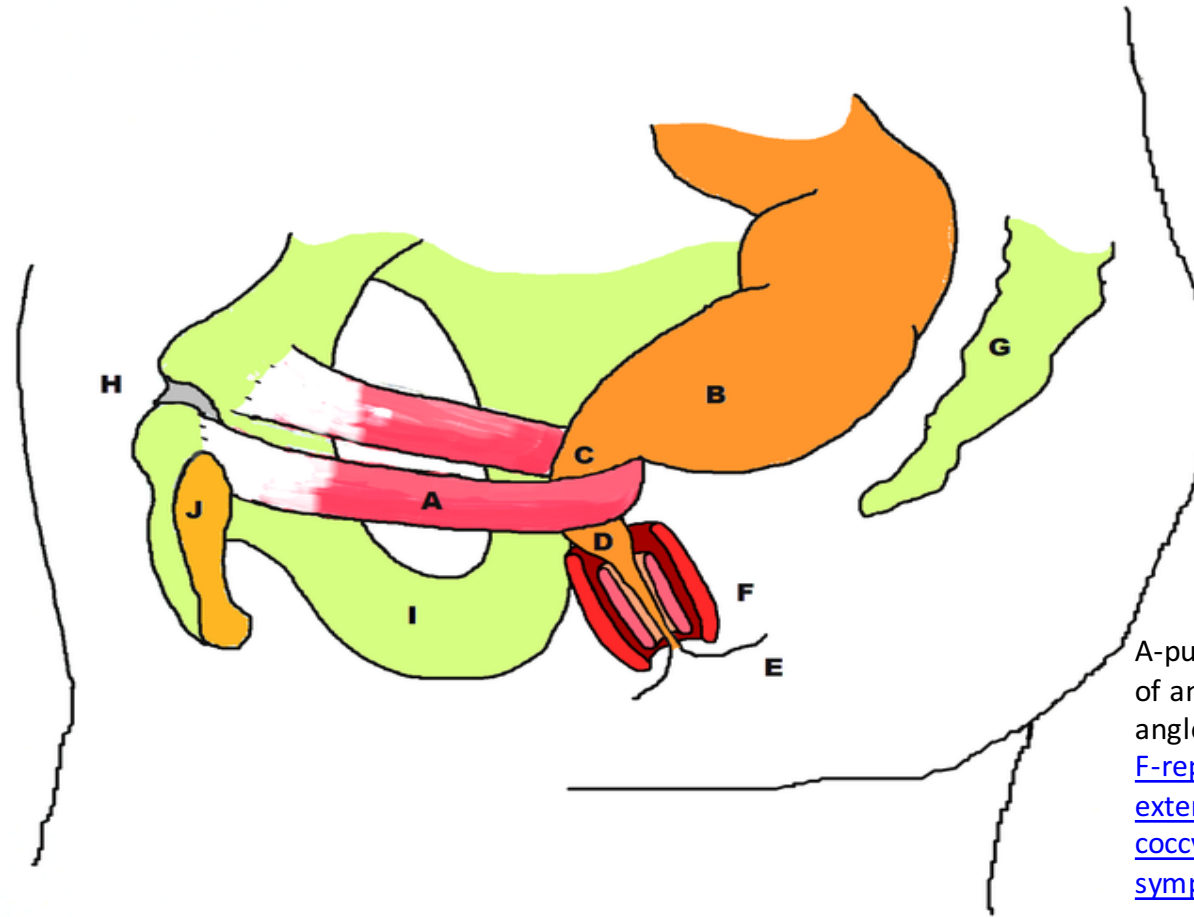
Who Am I

- Laparoscopic Colorectal and General surgeon
- Graduated from Royal college of Surgeons in Ireland
- Higher Surgical Training in East Anglia / cambridge Rotation.
- Laparoscopic Fellowship from New Zealand

Pelvic Floor MDT

- Meet once a month
- 3 Colorectal and 1 Urogynaecology
- Continence Team
- Complex cases and Management options.
- Welcome all referrals

Pelvic Anatomy



A-puborectalis, B-rectum, C-level of anorectal ring and anorectal angle, D-anal canal, E-[anal verge](#), F-[representation of internal and external anal sphincters](#), G-[coccyx & sacrum](#), H-[pubic symphysis](#), I-[ischium](#), J-[pubic bone](#)

Continence is Multifactorial

- Physiology and anatomy are co-dependant
- Largely Autonomic control with somatic over ride
- Sensory and Motor Nerves
- Muscle structural integrity and function
- Co-function of rectum, Anus, and pelvic floor .

Sphincter Mechanism

- Internal Anal Sphincter

- Closed Resting Anal tone 80-120 Poor 30
- Passive Function Autonomic
- Damaged passive Incontinence Leak

- External Anal sphincter

- Incremental Squeeze 140-180 Poor 50
- Active Function Pudendal nerve S2-4 Mixed
- Damaged Active incontinence Urgency, inability to delay.

Normal Physiological Events

- As rectal pressure rises, internal sphincter relaxes
“Recto-anal inhibitory reflex” (RAIR)
- Relaxation of IAS
 - Allows rectal contents to touch anal mucosa
 - Vital for discrimination
- Relaxation of Puborectalis/pubococcygeus
 - Allows recto-anal angle to straighten
 - ? Significance for incontinence, more an issue of obstructive defaecation
- Relaxation of external sphincter

Risk factors

- Vaginal delivery Forcipes, Large babies
- Anal surgery
 - Haemorrhoids, fissure, fistula
- Irritable bowel
- Inflammatory Bowel
- Radiotherapy
- Pelvic surgery
 - Anterior resection, Hysterectomy.

Child birth and Incontinence

- Obstetric trauma most common precursor FI
- 1 in 3 vaginal delivery will cause occult sphincter injury
- Peak incidence perimenopausal years
- Incontinence could be minor eg flatus, skid marks.
- Major eg FI

Baseline Clinical Assessment

- Onset when did it start?
- Bowel function Frequency consistency
- Urgency Straining
- Leakage and difficulty cleaning
- Bleeding, Pus, Pain, Prolapse
- Drug History Laxatives or anti-diarrhoeal
- PMH, Urogynae, Deliveries, Anal surgery

Baseline Clinical assessment

- Bristol faecal chart
- Wexner score/St Mark's fecal incontinence grading system (FIGS)
- Quality of life score
- Is it a problem for the patient? How much of a problem is it and how can we help them so they can manage.

Examination- Educated Finger

- Inspection:
 - Perineal Descent, soiling, excoriation, prolapse
- Resting Tone IAS May indicate nerve damage
- Squeeze EAS absent, present, flicker, maintained
- Mucozal or anal cannal pathology
- Perineal body damage
- sphincter muscle integrity.

Specialised Investigation

- Selected patients with severe score
- Failure of conservative measures
- Will benefit from surgical intervention
- If considering nerve stimulation

Specialised Investigations

- Endo anal US
- Anorectal Manometry
- Rectal capacitance- Volume studies

Biofeedback

- Rectal sensitivity training
 - Intra rectal balloon distension
- Sphincter strength training
 - Intra anal Emg probe
- Co-ordination Training
 - Squeez employed when RAIR is activated

Nerve Stimulation

- PTNS
 - Increasing popularity
 - Done in the area now
 - Awaiting introduction
- SNS
 - Still tertiary service provider
 - More invasive
 - Expensive.

Surgery

- Bio-injectables eg THD Gate Keeper
- Anterior sphincter repair with levatorplasty
- Rectopexy, prolapse repair.
- Stoma

Rectocele

- Weakening in the anterior Rectal wall leading to Vaginal Bulge.
- Presents with incomplete emptying leading to digitation (Obstructive defaecation).
- Perineal Bulge
- Posterior Vaginal repair may correct the Bulge but fails to improve the emptying!

Anterior Delormes

- Anterior Repair.
- Corrects anatomy and improves function as it corrects intussusceptions.

Rectal prolapse

- Must ask
- Size
 - Finger Tip Grape or Grapes
 - Fist Grapefruit

Bleeding, mucous, leak, Obstructive defaecation

Management

- Flexi Sig
- Perineal Sx
 - Delorme's
- Abdominal Sx
 - Laparoscopic Anterior Mesh Rectopexy
 - 48 hr hospital stay Enhanced Recovery.